

Anaphylactoid Syndrome of Pregnancy

Case Report

Jelšík I¹, Kis Pisti Š¹, Branna T², Štiglerová S¹, Volná P², Ožana M², and Kučera C¹

¹ Department of Anesthesiology and Resuscitation, City Hospital Ostrava, Czechia

² Department of Gynecology and Obstetrics, City Hospital Ostrava, Czechia

Abstract

The case study describes the development and treatment of Anaphylactoid syndrome of pregnancy, also known as amniotic fluid embolism, in a healthy secundigravida during labour. Anaphylactoid syndrome of pregnancy is a life-threatening obstetric complication, which is very difficult to diagnose and which requires fast and intensive therapy. In this case, severe coagulopathy occurred, with life-threatening bleeding to the abdominal cavity. Unfortunately, the bleeding was not possible to resolve by surgery at that time, and it was necessary to give the patient repeated transfusions and the coagulation factor VIIa (NovoSeven).

Keywords: Anaphylactoid syndrome of pregnancy; Coagulopathy; Peripartum haemorrhage; Amniotic fluid embolism

*Corresponding author

Štefan Kis Pisti,
Department of Gynecology and
Obstetrics,
ARO City Hospital Ostrava, Czechia,
Email: kispisti@seznam.cz

Article Information

Received: 12 April 2024;
Accepted: 12 April 2024;
Published: 27 April 2024.

Introduction

Anaphylactoid Syndrome of Pregnancy (ASP), also known as amniotic fluid embolism, is a rare, unpredictable, and one of the most serious obstetric complications with high maternal mortality. It is caused by the entry of amniotic fluid or its components into the maternal bloodstream during the peripartum period [1]. Fully developed ASP occurs in 1 in 800 to 1 in 80,000 pregnancies, with literature also reporting an incidence of 2–8 in 100,000 pregnancies [2,3]. The pathophysiology is not fully understood, but a combination of mechanical obstruction of vessels, inflammatory response, and hypersensitive immunological reaction of the mother is assumed [4].

ASP arises from a disruption of the uteroplacental and amniotic barrier, leading to the penetration of amniotic fluid into the mother's circulation. Amniotic fluid contains elements like prostaglandins, complement activators, and parts of fetal tissues (epithelia, lanugo, meconium, etc.) [4,5]. This leads to partial mechanical obstruction of the vessels and a massive inflammatory response. The change in terminology is also supported by the fact that fetal cells have been found in the circulatory system of physiologically healthy mothers, where no reaction or syndrome development occurred. Thus, it is more of an anaphylactic reaction to foreign material in the mother's bloodstream than an actual amniotic fluid embolism. Once amniotic fluid enters the bloodstream, it causes pulmonary vasoconstriction, leading to acute dilation of the right cardiac chambers. The increase in the volume of the right ventricle and bulging of the ventricular septum can be so significant that it reduces the systolic function of the left ventricle, increases pulmonary hypertension, and further reduces cardiac output. Hypoxia and hypotension lead to sudden cardiac failure. Meanwhile, the foreign material

in the vessels activates factors of the coagulation cascade. Pregnancy itself is a procoagulant state, with elevated levels of coagulation factors X, IX, VIII, von Willebrand Factor (VWF), and Tissue Factor Pathway Inhibitor (TFPI). In ASP, massive activation of inflammatory cytokines such as Placental Growth Factor (PLGF), Tumor Necrosis Factor-Alpha (TNF-alpha), interleukins, phospholipase A, and others has been recorded. Amniotic fluid in the maternal circulation activates coagulation factor III, stimulates platelet aggregation, and activates factor Xa, leading to severe coagulopathy and even disseminated intravascular coagulation, occurring in up to 80% of cases. Amniotic fluid has also been proven in uterine vessels, explaining the common symptom of ASP – hypotonia to uterine atony, which further deepens potential blood loss [5]. Other factors increasing the risk of ASP include: maternal age over 35 years, multiparity, placental disorders, polyhydramnios, and surgical delivery (cesarean section, forceps delivery, vacuum extraction) [2,6].

Diagnosis is per exclusionem. Symptoms are diverse and develop suddenly. They most commonly include encephalopathy, respiratory distress, cardiovascular collapse to circulatory arrest, coagulopathy, and in full expression of the syndrome, acute renal failure. The fetus is at risk of asphyxia before delivery. Symptoms are similar to other conditions that need to be ruled out in differential diagnosis (embolisms other than ASP, eclampsia, aspiration of gastric contents, hemorrhage, anesthetic toxicity, anaphylactic reaction, transfusion reaction, cardiopulmonary failure, etc.).

Laboratory findings include acidosis, hypofibrinogenemia, prolonged APTT, INR, and coagulopathy of varying degrees in viscoelastic blood examinations. Specific laboratory tests (levels of C3, C4 complement, tryptase level, insulin growth factor

binding protein-1) are limitedly available and yield late results [4]. The treatment is symptomatic, necessitating multidisciplinary cooperation. From the intensivist's perspective, the goals include maintaining oxygenation, circulatory stabilization, and treating coagulopathy. From the obstetrician's viewpoint, the focus is on terminating the pregnancy and controlling uterine bleeding [7].

Case Study

A 34-year-old primigravida at 41+1 weeks of physiological pregnancy following spontaneous conception, with no internal comorbidities, was currently on ferrotherapy for mild anemia in pregnancy. Her history included 2 laparoscopic surgeries - in 2016 for ovarian cyst resection, and in 2017 for third-stage endometriosis and adhesiolysis, followed by uterine cavity revision after the first birth. Her weight was 70 kilograms and height 161 centimeters. We admitted the patient in the evening due to the onset of uterine activity, without amniotic fluid leakage, and repeatedly normal Cardiotocography (CTG). The next day, there was almost no progression in the birth canal. Due to post-term pregnancy and maternal exhaustion, we initiated induction of labor with PGE2. Despite regular tonicity, after rupturing the amniotic sac, the vaginal findings remained the same. Due to pathological CTG (Figure 1) and non-progressing labor in the first stage, we indicated a cesarean section (SC).

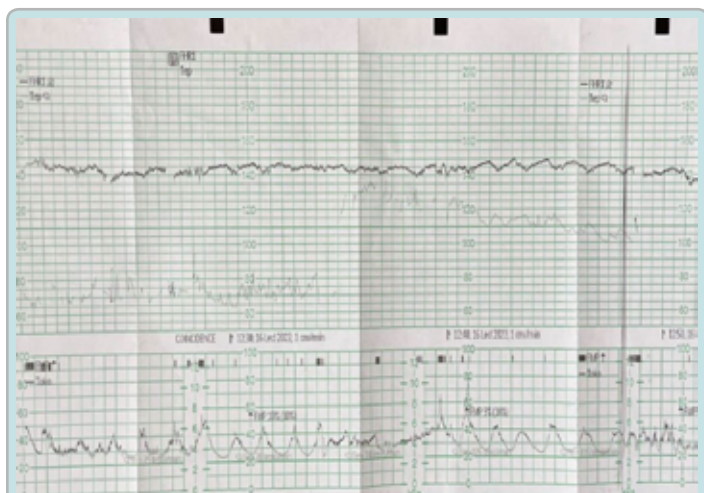


Figure 1: Pathological cardiotocography recording immediately before urgent cesarean section.

We started preoperative preparation, taking blood samples for complete blood count, INR (Table 1 Column 2). At this stage, the patient's behavior changed - she became apathetic, had slowed psychomotor tempo, responded with latency, and appeared confused. This was also confirmed by her private midwife, who had been caring for the patient since the beginning of the pregnancy. We proceeded with SC under General Anesthesia (GA) due to the patient's refusal of spinal anesthesia. After delivering a physiologically healthy newborn, APGAR score 10-10-10, the placenta was manually removed. The procedure was then complicated by uterine hypotonia. A revision of the uterine cavity was performed, but hypotonia persisted, so we administered uterotonics in this order: intravenous oxytocin bolus + continuously, methylergometrine intravenously, misoprostol rectally, carboprost into the myometrium. The uterotonics had a good effect, and the uterus contracted further.

Upon checking the uterotomy and abdominal cavity, we found no bleeding. The operation lasted 40 minutes, with a total blood loss of 700 milliliters. During recovery from anesthesia, the patient's consciousness deteriorated, she became hypotensive and tachycardic. We secured a second peripheral venous catheter and took blood for complete blood count and coagulation tests – hemoglobin 104 g/l, fibrinogen 0.38 g/l (Table 1 Column 3). Mild vaginal bleeding persisted in the gynecological post anaesthetic care unit PACU, not corresponding to the patient's worsening clinical condition. Considering the developing coagulopathy, we administered 1 gram of tranexamic acid and 4 grams of fibrinogen /HAEMOCOMPLETTAN/, and continued volume therapy with crystalloids. To further investigate the coagulopathy, we took a sample for tromboelastographic ROTEM analysis. The patient's circulatory instability and altered consciousness worsened with minimal bleeding from the genital tract. Given the deteriorating clinical condition, we indicated urgent laparotomy with abdominal cavity revision (1 hour and 43 minutes post-SC). Upon arrival in the operating room, she was unconscious, bradypnoeic, with immeasurable blood pressure, and threadlike peripheral pulses. Fluid resuscitation was initiated (crystalloid, colloid - 6% hydroxyethyl starch, and 5% albumin), positively impacting circulatory stabilization. Simultaneously with the surgery, ROTEM results (Figure 2) were available, leading us to consider ASP for the first time in the differential diagnosis. The leading anesthesiologist and head of the gynecology department were present.

Table 1: Laboratory examination.

Time of blood sampling	42.min before CS	Immediately after CS	After arrival to ICU	Next day 9:10 a.m.
INR	0.92	1.8	0.92	1.08
APTT (s)		58	60.1	37.3
Fibrinogen g/l		0.38	1.65	2.43
Hemoglobin (g/l)	129	104	63	58
Hematocrit	0.372	0.297	0.186	0.161
Platelets 109/l	195	201	67	73
Ph arterial			7.087	7.35
Lactate arterial (mmol/l)			9.15	7.6

We administered another 4 grams of fibrinogen, and 10 minutes into the procedure, due to severe coagulopathy, we administered 5 milligrams of factor VIIa /NOVOSEVEN/, followed by 3 units of Red Blood Cells (RBC), 3 units of Fresh Frozen Plasma (FFP). No significant blood loss explaining the severe circulatory instability was found in the abdominal cavity preoperatively. Due to findings on the uterus (recurring uterine hypotonia), progressing clinical condition, and exhaustion of conservative therapy options, we indicated a hysterectomy for vital reasons – the procedure went without complications. The total blood loss (revision with hysterectomy + SC) was estimated at 1500 milliliters. Postoperatively, the patient remained unconscious, without spontaneous respiratory activity, necessitating vasopressor support, and was transferred to the anesthesiology and resuscitation department (ARO) on mechanical ventilation. Given persistent consciousness disturbance, a brain CT with CT angiography was performed en route to ARO, showing no signs of bleeding or ischemia, but both internal carotid arteries (ACI) were very slender, resembling vasospasm in the cervical segments of ACI (Figure 3a,3b).

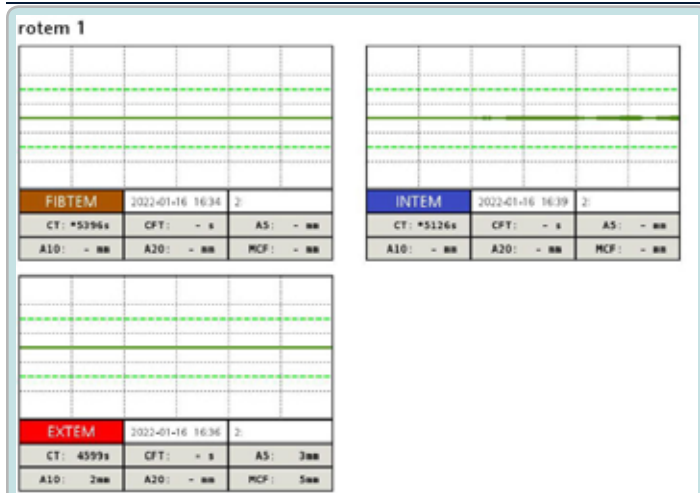


Figure 2: Tromboelastography ROTEM after cesarean section, showing serious disorder of coagulation.



Figure 4: Tromboelastography ROTEM after urgent hysterectomy, showing still affected coagulation.

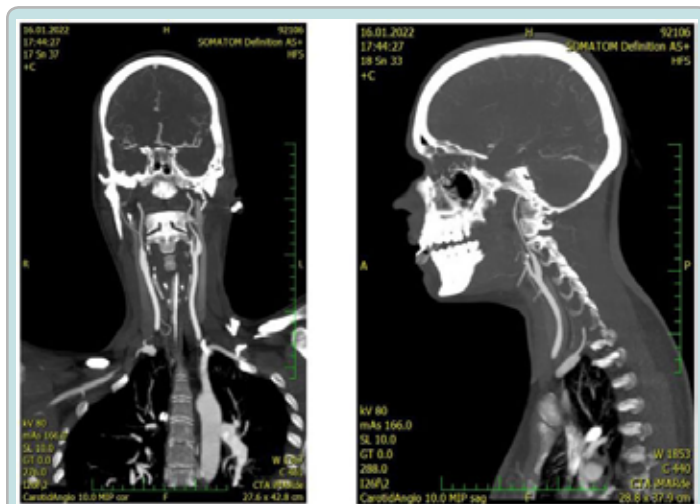


Figure 3a, 3b: CT scans with vasospasms of cervical segments of internal carotid arteries.

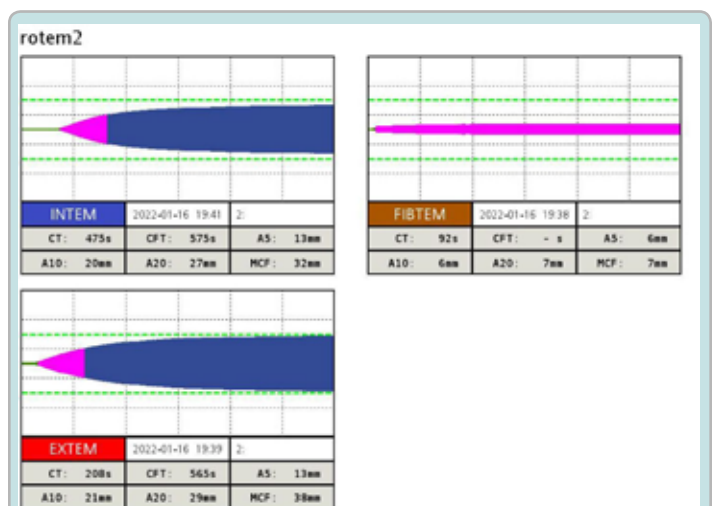

Figure 5: Tromboelastography before operation for intraabdominal bleeding, after repeated administration of Factor VIIa.

On ARO, vasopressor support continued, along with protective mechanical ventilation and massive transfusion protocol. Transthoracic echocardiography showed borderline signs of right ventricular diastolic dysfunction and possible pulmonary hypertension, but good systolic function and contractility in both ventricles with a left ventricular Ejection Fraction (EF) of 55%. We repeatedly conducted coagulation tests, both standard laboratory and tromboelastography ROTEM (Figure 4), in the clinical context of profuse bleeding, especially around invasive entries and into the abdominal cavity as part of consumptive coagulopathy. After consulting with a hematologist, we prepared and administered another 9 mg of factor VIIa, leading to coagulation correction according to ROTEM (Figure 5). During the first postoperative day, we undertook operative revision as part of damage control surgery procedures. We evacuated approximately 6 liters of blood from the abdominal cavity during the operative revision, but the source of bleeding was not apparent. The total blood loss since hospitalization was 10 liters (2.5 liters in drains). In the next abdominal revision (1st postoperative day), no bleeding signs were found, and we proceeded to definitive suturing of the laparotomy.

In the following days, we reduced analgosedation, and the patient initially showed signs of cognitive dysfunction, gradually improving. We began weaning her from mechanical ventilation and administered antibiotics empirically.

We extubated on the 6th day, after which she remained respiratory sufficient, with a tendency towards hypertension, and was discharged home on the 21st day through the gynecological PACU and standard department, without neurological deficits. In the following weeks, we completed comprehensive hematological examination, which showed no pathological findings. During hospitalization, a total of 35 units of FFP, 36 units of RBC, 8 units of platelet concentrate, 1200 units of coagulation factors (Prothromplex), 29 grams of fibrinogen, 14 milligrams of factor VIIa, and repeated doses of tranexamic acid were administered.

Discussion

The diagnosis of ASP is challenging, and it is crucial to consider ASP in differential diagnoses. The syndrome presents with a wide range of symptoms across various organ systems, with the onset speed and symptom intensity varying significantly among

individuals. This can lead to fatal delays in therapy. In our case, we initially ruled out other diagnoses, particularly hemorrhagic shock due to blood loss from uterine hypotonia. However, it's important to remember that uterine hypotonia or atony, as mentioned earlier, is one of the symptoms of ASP. Yet, the total blood loss did not correspond to the rapidly progressing clinical picture of the patient. In our case, the initiation of ASP treatment was prompted by persistent alteration in consciousness, severe circulatory instability disproportionate to blood loss, hypofibrinogenemia, and severe coagulopathy according to ROTEM. The onset of fully expressed symptoms in this case occurred within tens of minutes, and there was no circulatory arrest, which provided more time for diagnosis recognition. Subsequently, we promptly and aggressively initiated treatment for coagulopathy, including repeated administration of factor VIIa for surgically unresolvable bleeding. In other cases, however, cardiac arrest can occur very quickly, limiting the time window for adequate response.

Key to our approach was the close interdisciplinary collaboration between the gynecologist, anesthesiologist, intensivist, and hematologist, with subsequent involvement of additional consultants (radiologist, cardiologist, surgeon). Specific tests confirming the diagnosis were not performed due to their unavailability at our facility and their time-consuming nature. An early indicator can be low fibrinogen levels while hemoglobin and hematocrit may remain within the reference range. During the preparation of this article, the authors, including the leading midwife, met with the patient. She reported not recalling events following the initiation of labor induction and rupture of the amniotic sac, until the reduction of analgesation at ARO, where she regained full consciousness. At this stage (first stage of labor), we also noted a change in the mother's behavior and pathological CTG findings, which could have been the onset of ASP symptoms.

Alteration in consciousness with significant behavioral change during hypoxic-ischemic encephalopathy is often an initial symptom of ASP.

Conclusion

By documenting this case study, we aim to highlight this life-threatening syndrome, whose incidence may not be as rare as thought, thus necessitating familiarity with its diagnostic and therapeutic procedures. We believe the added value of this case study lies in the timely detection of a bizarre coagulation disorder (ROTEM, coagulogram) and the finding of bilateral ACI vasospasms, which could explain the cause of brain hypoxia leading to altered consciousness and behavioral changes.

References

1. Steven LC. (2014). Amniotic Fluid Embolism. *Obstet Gynecol.* 123: 337-348.
2. Heřman H, Faridová AT, Volfová M, Džuponová G, Hostinská E, et al. (2022). Amniotic fluid embolism - review and multicentric case analysis. *Ceska Gynekol.* 87: 261-268.
3. Sarka Lisonkova 1, Michael S Kramer. (2019). PLoS One Amniotic fluid embolism: A puzzling and dangerous obstetric problem. 16: e1002976.
4. Černý A, Paris A, Šimják P. (2015). Pathophysiology and diagnosis of anaphylactoid pregnancy syndrome. *Anest. intensive Med.* 5: 291-296.
5. Haftel A, Chowdhury YS. (2022). Amniotic Fluid Embolism. In: *StatPearls [Internet]. Treasure Island (FL): StatPearls Publishing. PMID: 32644533.*
6. Antonín P. (2012). Critical conditions in obstetrics. 285.
7. Pavel S, Martin M. (2014). Monograph. revision. and distr. 1195.